INTERNATIONAL JOURNAL OF PHARMACEUTICAL SCIENCES
[ISSN: 0975-4725; CODEN(USA): IJPS00]
Journal Homepage: https://www.ijpsjournal.com

OPEN ACCESS

Review Article

Beyond Neurofibroma: An Unusual Giant Posterior Truncal Lipomatous Lesion in an Elderly Patient- a Clinicoradiological Diagnostic Challenge

Alfeena N.[1*], Nandana R. S.[2], Grace N. Raju[3], Dr. Azeem Mohammed Basheer[4], Shaiju S. Dharan[5]

[1,2] Pharm D Students, Ezhuthachan College of Pharmaceutical Sciences, Marayamuttom Neyyattinkara, Thiruvananthapuram,
[3] Assistant Professor, Department of Pharmacy Practice, Ezhuthachan College of Pharmaceutical Sciences, Marayamuttom Neyyattinkara, Thiruvananthapuram.
[4] Consultant General Surgeon at Nims Medicity Neyyattinkara, Thiruvananthapuram.
[5] HOD/Principal, Department of Pharmacy Practice, Ezhuthachan College of Pharmaceutical Sciences, Marayamuttom Neyyattinkara, Thiruvananthapuram.

ARTICLE INFO

Published: 26 Nov 2026
Keywords:
Giant plexiform neurofibroma, Peripheral nerve sheath tumour, Paraspinal mass, Surgical excision, Skin grafting, Multidisciplinary management
DOI:
10.5281/zenodo.24548914

ABSTRACT

Giant plexiform neurofibroma is an uncommon benign peripheral nerve sheath tumour characterized by diffuse involvement of multiple nerve fascicles and extensive infiltration of surrounding soft tissues. Although these lesions are generally slow-growing, their progressive enlargement can result in significant physical deformity, functional impairment and difficulties in surgical management. Large plexiform neurofibromas involving the posterior trunk are particularly challenging because of their extensive anatomical involvement and the potential for deeper structural extension. An 82-year-old male with a known history of Type 2 diabetes mellitus, Dyslipidaemia, and Hypertension presented with a progressively enlarged, extensive mass over the back of the trunk, predominantly involving the paraspinal and thoracic regions. Following clinical and radiological evaluation, the patient was diagnosed with giant plexiform neurofibroma. Imaging assessment revealed extensive soft-tissue involvement without evidence of underlying bony involvement or extension into the spinal cord. Further investigations were performed to assess his general condition and suitability for surgical intervention. Considering the extensive size of the lesion and the associated clinical concerns, multidisciplinary evaluation was undertaken, including Cardiology,

***Corresponding Author:** Alfeena N.
Address: Pharm D Students, Ezhuthachan College of Pharmaceutical Sciences, Marayamuttom Neyyattinkara, Thiruvananthapuram
Email ✉: www.alfeenanoushad001@gmail.com

Relevant conflicts of interest/financial disclosures: The authors declare that the research was conducted in the absence of any commercial or financial relationships that could be construed as a potential conflict of interest.

Pulmonology, General medicine, and Plastic surgery consultations.After appropriate preoperative assessment and optimization, the patient underwent surgical excision of the plexiform neurofibroma with skin grafting of the resulting raw area under general anaesthesia. Postoperatively, he was monitored in the surgical intensive care unit and received intravenous antibiotics, analgesics, and supportive treatment. Subsequently, wound debridement was performed under general anaesthesia on 27 April 2026. The patient's postoperative recovery was satisfactory, with gradual clinical improvement. Following stabilization, he was transferred to the general ward and discharged in stable condition with appropriate medical advice. Early evaluation and individualized surgical planning are essential for managing extensive plexiform neurofibromas and improving patient outcomes.

INTRODUCTION

Plexiform neurofibroma is an uncommon, benign peripheral nerve sheath tumour that arises from multiple nerve fascicles and may extend extensively into the surrounding soft tissues. It is most frequently associated with neurofibromatosis type 1, a genetic disorder characterized by the development of multiple neural tumours and other systemic manifestations. Although these tumours are histologically benign, their progressive growth can result in considerable anatomical distortion, functional impairment, pain, and cosmetic complications.[1,2] Plexiform neurofibromas can occur in different anatomical regions, including the head, neck, trunk, and extremities. Lesions involving the posterior trunk and paraspinal regions may present particular clinical challenges because of their extensive involvement of skin and subcutaneous tissues and their potential proximity to important anatomical structures. Large lesions may progressively increase in size, resulting in significant deformity and difficulties in achieving complete surgical removal.[2,3]

The diagnosis of plexiform neurofibroma primarily involves clinical assessment and radiological investigations to determine the extent of tumour involvement and its relationship with adjacent structures. Computed tomography (CT) and magnetic resonance imaging (MRI) are valuable in evaluating tumour dimensions, soft-tissue extension, and possible involvement of underlying bone or neural structures. Histopathological examination, when available, further contributes to diagnostic confirmation. Careful preoperative assessment is particularly important in patients with giant lesions to facilitate appropriate surgical planning and minimize potential complications.[2,3] Surgical excision remains an important treatment option for plexiform neurofibromas, particularly when lesions produce significant deformity, functional limitations, or other clinical concerns. However, complete removal may be challenging because of extensive tissue involvement, vascularity, and poorly defined tumour margins. In cases involving large soft-tissue defects following excision, reconstructive procedures such as skin grafting may be required to achieve adequate wound coverage. A multidisciplinary approach involving general surgery, plastic surgery, cardiology, pulmonology, and general medicine can help optimize perioperative management, particularly in elderly patients with associated comorbidities.[2,4] The present case highlights the clinical and surgical challenges of managing a giant plexiform neurofibroma involving the paraspinal and thoracic regions in an elderly patient with multiple comorbidities, emphasizing the importance of individualized surgical planning, multidisciplinary management, and reconstructive intervention in achieving a favourable clinical outcome.

CASE PRESENTATION

An 82-year-old male patient was admitted to the Department of General Surgery with complaints of a progressively enlarging, huge soft-tissue mass over the back of the trunk, predominantly involving the paraspinal and thoracic regions. The patient was a known case of Type 2 diabetes mellitus, Dyslipidaemia and Hypertension. Following clinical evaluation, he was diagnosed with giant plexiform neurofibroma and admitted for further management. On admission, the patient was conscious, alert and well oriented.

Laboratory Investigations

- Haematological Investigations

Complete blood count revealed anaemia, with haemoglobin approximately 9.9g/dL and haematocrit of 30.8%. Total leukocyte count was markedly elevated, reaching approximately 40,350 cells/mm³, with subsequent values around 40,270 cells/mm³, indicating significant leucocytosis.

- Radiological Investigations

Contrast-enhanced CT of the abdomen and pelvis demonstrated a large, lobulated, exophytic cutaneous and subcutaneous soft-tissue mass involving the back and thoracic region. The lesion extended across the paraspinal region, with heterogeneous enhancement and multiple lobulated components. No evidence of underlying bony destruction or spinal canal extension was identified. Additional findings included prostatomegaly and a small round soft-tissue lesion arising from the head and neck region of the pancreas, for which further evaluation was recommended.

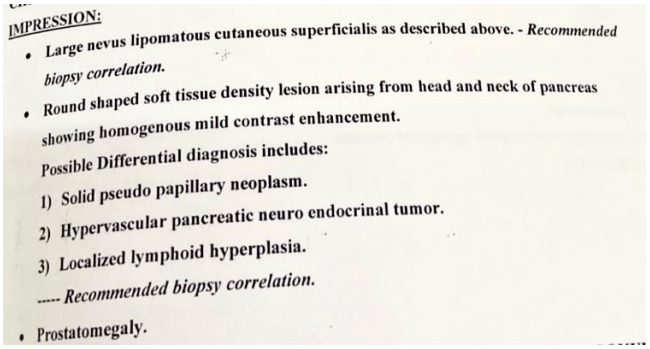
IMPRESSION:

- Large nevus lipomatous cutaneous superficialis as described above. - *Recommended biopsy correlation.*
- Round shaped soft tissue density lesion arising from head and neck of pancreas showing homogenous mild contrast enhancement.

Possible Differential diagnosis includes:

1) Solid pseudo papillary neoplasm.
2) Hypervascular pancreatic neuro endocrinal tumor.
3) Localized lymphoid hyperplasia.

----- *Recommended biopsy correlation.*

- Prostatomegaly.

Figure 1: ***CT Scan Abdomen and Pelvis***

- Histopathological Examination

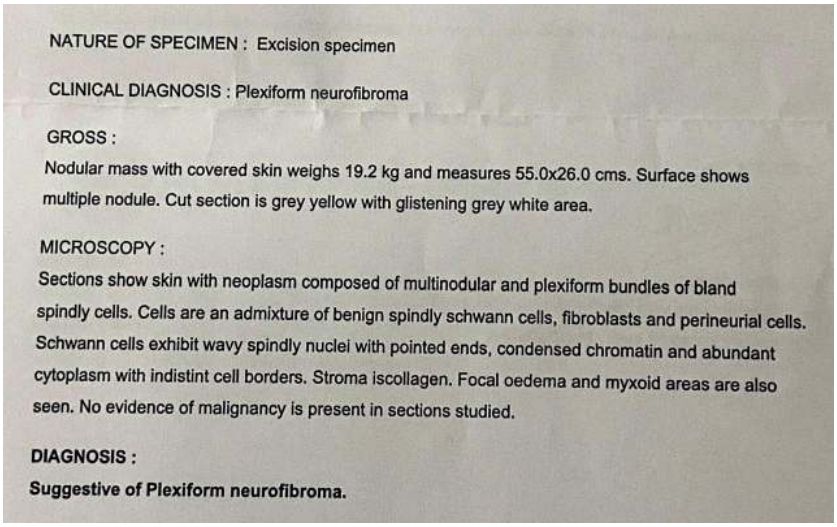
NATURE OF SPECIMEN : Excision specimen

CLINICAL DIAGNOSIS : Plexiform neurofibroma

GROSS :

Nodular mass with covered skin weighs 19.2 kg and measures 55.0x26.0 cms. Surface shows multiple nodule. Cut section is grey yellow with glistening grey white area.

MICROSCOPY :

Sections show skin with neoplasm composed of multinodular and plexiform bundles of bland spindly cells. Cells are an admixture of benign spindly schwann cells, fibroblasts and perineurial cells. Schwann cells exhibit wavy spindly nuclei with pointed ends, condensed chromatin and abundant cytoplasm with indistint cell borders. Stroma iscollagen. Focal oedema and myxoid areas are also seen. No evidence of malignancy is present in sections studied.

DIAGNOSIS :

Suggestive of Plexiform neurofibroma.

Figure 2: ***Histopathology Report***

Histopathological examination of the excised lesion confirmed the diagnosis of giant neurofibroma, supporting the clinical & radiological diagnosis of plexiform neurofibroma. This tissue-based confirmation established the nature of the large soft-tissue lesion and helped distinguish it from other soft-tissue neoplasm

- Microbiological Investigations

Pus swab culture demonstrated heavy growth of Citrobacter freundii. Antibiotic susceptibility testing was performed to guide appropriate antimicrobial management.

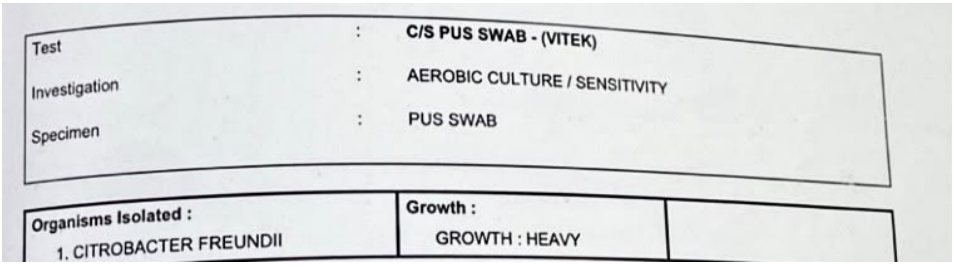
Test	:	C/S PUS SWAB - (VITEK)
Investigation	:	AEROBIC CULTURE / SENSITIVITY
Specimen	:	PUS SWAB

Organisms Isolated :	Growth :
1. CITROBACTER FREUNDII	GROWTH : HEAVY

Figure 3: ***Pus Culture and Sensitivity***

Clinical Course

An 82-year-old male was admitted to the Department of General Surgery on 13 April 2026 with complaints of a progressively enlarged, extensive mass over the back of the trunk, predominantly involving the paraspinal and thoracic regions. Following clinical and radiological evaluation, he was diagnosed with giant plexiform neurofibroma. Imaging assessment indicated

extensive soft-tissue involvement without evidence of underlying bony involvement or spinal cord extension. Echocardiography revealed regional wall motion abnormality (RWMA) in the right coronary artery territory with fair left ventricular systolic function. During the subsequent hospital stay, the patient received intravenous antibiotics, analgesics, and other supportive medications. CRP levels also remained elevated during the postoperative period. Following surgical intervention and supportive treatment, the patient showed satisfactory clinical improvement. He was subsequently discharged on 4 May 2026 in a stable condition with appropriate medications, wound-care instructions, and follow-up advice.



Before Surgery



After Surgery

DISCUSSION

Plexiform neurofibroma is an uncommon benign peripheral nerve sheath tumour characterized by the proliferation of Schwann cells and other components of the peripheral nerve sheath. These tumours typically involve multiple nerve fascicles and extend along the course of peripheral nerves, resulting in diffuse infiltration of surrounding tissues. They are strongly associated with neurofibromatosis type1, although the presence of a plexiform neurofibroma alone does not establish the diagnosis of NF1.[3,4] Despite their benign histological nature, these lesions may progressively enlarge and cause considerable physical deformity, functional limitations, and difficulties in surgical management.[3,5]

Liu L, Fan J et al. reported a giant plexiform neurofibroma involving the entire back in an adolescent female, managed by total surgical resection and autologous tumour skin grafting. In contrast, the present case involved an 82-year-old male with multiple comorbidities, requiring surgical excision, skin grafting, postoperative ICU monitoring and subsequent wound debridement, highlighting the challenges of managing extensive plexiform neurofibromas in elderly patients[3].

Giant plexiform neurofibromas involving the posterior trunk and paraspinal regions are particularly challenging because of their extensive soft-tissue involvement and proximity to important anatomical structures. Progressive enlargement may result in substantial tissue distortion and create difficulties in achieving complete surgical removal and subsequent wound reconstruction. In addition, these lesions may demonstrate increased vascularity, which can contribute to significant intraoperative blood loss and postoperative complications.[5,6] Therefore, careful assessment of tumour extent and the patient's general condition is essential before undertaking surgical intervention.[6]

In the present case, an 82-year-old male presented with a progressively enlarging, extensive mass over the back of the trunk involving the paraspinal and thoracic regions. The clinical diagnosis was giant plexiform neurofibroma, with imaging assessment indicating no underlying bony involvement or spinal cord extension. The patient also had associated comorbidities, including Type 2 diabetes mellitus, Dyslipidaemia, and Hypertension. These conditions increased the complexity of perioperative management and required appropriate medical optimization before surgery. The advanced age of the patient further emphasized the importance of

careful anaesthetic evaluation and multidisciplinary assessment.[6,7] Laboratory investigations revealed anaemia, with haemoglobin levels ranging approximately from 9.9 to 10.9 g/dL during the hospital stay. Inflammatory markers were elevated, with C-reactive protein reaching 141.1 mg/L . The total leukocyte count also demonstrated postoperative variations, increasing from 10,350 cells/mm³ on 14 April to 15,710 cells/mm³ on 29 April 2026. These findings indicated the need for continued monitoring of inflammatory status and possible postoperative complications. Renal function remained relatively preserved, with serum creatinine values within the reported reference range. Liver function investigations were also largely unremarkable. Preoperative cardiovascular assessment was particularly important because the patient had multiple cardiovascular risk factors. Echocardiography demonstrated regional wall motion abnormality involving the right coronary artery territory, with fair left ventricular systolic function. Accordingly, cardiology, pulmonology, general medicine, and plastic surgery consultations were obtained to evaluate and optimize the patient before surgical intervention. This multidisciplinary approach helped address the potential perioperative risks associated with advanced age and multiple comorbidities.[6,7] Surgical excision remains an important treatment option for plexiform neurofibromas when lesions produce significant deformity, functional impairment, or other clinical concerns. However, complete excision may be difficult because of their infiltrative growth pattern and involvement of surrounding tissues. The extent of surgery must therefore be individualized according to tumour size, anatomical location, expected functional outcomes, and the patient's overall clinical condition. Reconstruction of the resulting tissue defect is an essential component of management when extensive skin and soft-tissue removal is required.[5,8] In this patient, surgical excision of the giant plexiform neurofibroma with skin grafting of the resulting raw area was performed under general anaesthesia on 16 April 2026. Considering the patient's postoperative risk profile, he was initially monitored in the surgical intensive care unit before being transferred to the general ward. During the subsequent hospital stay, he received intravenous antibiotics, analgesics, and other supportive medications. Wound debridement was subsequently performed under general anaesthesia on 27 April 2026 to facilitate appropriate wound management. The postoperative course was reported to be uneventful, and the patient demonstrated satisfactory clinical improvement before discharge. An important consideration in the long-term management of plexiform neurofibromas is the possibility of malignant transformation into malignant peripheral nerve sheath tumours, particularly in patients with NF1.[3,9] Rapid tumour enlargement, new or progressively worsening pain, changes in tumour consistency, and the development of neurological deficits should raise suspicion of malignant transformation. Such clinical changes warrant further radiological evaluation and, when indicated, histopathological assessment.[9,10]Long-term clinical monitoring is therefore important, particularly following incomplete excision. Regional MRI is particularly useful when symptoms or changes in tumour behaviour raise concern for progression or malignant transformation.[9,10] Surgical intervention should be considered when clinically indicated, while treatment decisions should account for the potential benefits and associated functional risks. The present case is clinically noteworthy because of the extensive paraspinal and thoracic involvement of the tumour in an elderly patient with multiple medical comorbidities. Successful surgical excision, skin grafting, subsequent wound debridement, and supportive postoperative management resulted in satisfactory clinical stabilization and discharge.

This case highlights the importance of individualized surgical planning, multidisciplinary coordination, appropriate reconstructive techniques, and continued postoperative surveillance in the management of giant plexiform neurofibromas.[5,6,9]

CONCLUSION

This case highlights the clinical challenges involved in the management of a giant plexiform neurofibroma in an elderly patient with multiple comorbidities, including type 2 diabetes mellitus, hypertension, and dyslipidaemia. The extensive mass involving the posterior trunk and paraspinal and thoracic regions required careful clinical assessment, radiological evaluation, and multidisciplinary management. Although the

patient's advanced age and associated medical conditions increased the complexity of perioperative care, surgical excision of the lesion with skin grafting was successfully performed under general anaesthesia. Postoperative monitoring in the surgical intensive care unit, supportive treatment, and subsequent wound debridement contributed to the management of the surgical wound. The patient showed satisfactory clinical progress and was discharged in a stable condition.

This case emphasizes the importance of early recognition, appropriate preoperative assessment, and individualized surgical planning in patients presenting with giant plexiform neurofibromas. It also demonstrates the value of coordinated care involving general surgery, plastic surgery, cardiology, pulmonology, and general medicine, particularly in elderly patients with underlying comorbidities. Long-term clinical follow-up is important to monitor wound healing, detect possible recurrence, and identify any changes suggestive of malignant transformation.

REFERENCES

1. Liu L, Fan J, Gan C, Tian J, Jiao H. Total resection of giant plexiform neurofibroma of the entire back in one stage by autologous tumor skin graft. J Plast Reconstr Aesthet Surg. 2012;65 (2):276-7. doi:10.1016/j.bjps.2011.08.017.
2. Park JH, Kim JR, Shin SJ, Lee NH, Lee HS, Lim YJ. Use of tissue expansion to allow reconstruction of the back after wide resection of a diffuse neurofibroma. J Plast Surg Hand Surg. 2011;45 (4-5):244-7. doi:10.3109/2000656X.2011.573920.
3. Gutmann DH, Ferner RE, Listernick RH, Korf BR, Wolters PL, Johnson KJ. Neurofibromatosis type 1. Nat Rev Dis Primers. 2017;3:17004. doi:10.1038/nrdp.2017.4.
4. Legius E, Messiaen L, Wolkenstein P, Pancza P, Avery RA, Berman Y, et al. Revised diagnostic criteria for neurofibromatosis type 1 and Legius syndrome: an international consensus recommendation. Genet Med. 2021;23 (8):1506-13. doi:10.1038/s41436-021-01170-5.
5. Gross AM, Singh G, Akshintala S, Baldwin A, Dombi E, Ukwuani S, et al. Association of plexiform neurofibroma volume changes and development of clinical morbidities in neurofibromatosis 1. Neuro Oncol. 2018;20 (12):1643-51. doi:10.1093/neuonc/noy067.
6. Prada CE, Rangwala FA, Martin LJ, Lovell AM, Saal HM, Schorry EK, et al. Pediatric plexiform neurofibromas: impact on morbidity and mortality in neurofibromatosis type 1. J Pediatr. 2012;160 (3):461-7. doi:10.1016/j.jpeds.2011.08.051.
7. Dombi E, Baldwin A, Marcus LJ, Fisher MJ, Weiss B, Kim A, et al. Activity of selumetinib in neurofibromatosis type 1-related plexiform neurofibromas. N Engl J Med. 2016;375 (26):2550-60. doi:10.1056/NEJMoa1605943.
8. Acar S, Armstrong AE, Hirbe AC. Plexiform neurofibroma: shedding light on the investigational agents in clinical trials. Expert Opin Investig Drugs. 2022;31 (1):31-40. doi:10.1080/13543784.2022.2022120.
9. Fisher MJ, Blakeley JO, Weiss BD, Dombi E, Ahlawat S, Akshintala S, et al. Management of neurofibromatosis type 1-associated plexiform neurofibromas. Neuro Oncol. 2022;24 (11):1827-44. doi:10.1093/neuonc/noac146.
10. Carton C, Evans DG, Blanco I, Friedrich RE, Ferner RE, Farschtschi S, et al. ERN GENTURIS tumour surveillance guidelines for individuals with neurofibromatosis type 1. EClinicalMedicine. 2023;56:101818. doi:10.1016/j.eclinm.2022.101818.
11. Collins-Sawaragi YC, Ferner R, Vassallo G, De Agrò G, Eccles S, Cadwgan J, et al. Location, symptoms, and management of plexiform neurofibromas in 127 children with neurofibromatosis 1, attending the National Complex Neurofibromatosis 1 service, 2018-2019. Am J Med Genet A. 2022;188 (6):1723-7. doi:10.1002/ajmg.a.62691.
12. Hwang JK, Kim SH, Kim DS. Treatment of plexiform neurofibromas: current perspectives on surgery and medical treatment. J Korean Neurosurg Soc. 2025;68 (3):252-60. doi:10.3340/jkns.2025.0041.
13. Bicer A, Karadag HE, Topaloglu E, Gokturk RA, Uysal E, Kaya H, et al. Staged resection and

reconstruction of a 60-kg giant plexiform neurofibroma involving the posterior trunk and thigh. Plast Reconstr Surg Glob Open. 2026;14 (8):e8001. doi:10.1097/ GOX.0000000000008001.

14. Ghajar K, Elsherbini A, Volfson E, Yakubov R, Baltzer HL, Suppiah S, et al. Surgical management of plexiform neurofibromas: an imaging-based perioperative framework. JPRAS Open. 2026;52:111-20. doi:10.1016/j.jpra.2026.08.006.

HOW TO CITE: Alfeena N., Nandana R. S., Grace N. Raju, Dr. Azeem Mohammed Basheer, Shaiju S. Dharan, Beyond Neurofibroma: An Unusual Giant Posterior Truncal Lipomatous Lesion in an Elderly Patient- a Clinicoradiological Diagnostic Challenge, Int. J. of Pharm. Sci., 2026, Vol 4, Issue 11, 4911-4917. https://doi.org/10.5281/zenodo.24548914