INTERNATIONAL JOURNAL OF PHARMACEUTICAL SCIENCES
[ISSN: 0975-4725; CODEN(USA): IJPS00]
Journal Homepage: https://www.ijpsjournal.com

Review Article

Coexisting Penile Squamous Cell Carcinoma and Condyloma Acuminatum of the Penile Foreskin in a Young Adult with Balanitis Xerotica Obliterans: A Case Report

Vibisha Victor[1*], Darsana Radhika[2], Drishya L.[3], G. S. Jeevan[4], Shaiju Dharan[5]

[1,2] Pharm D Interns, Ezhuthachan College of Pharmaceutical Sciences, Marayamuttom, Thiruvananthapuram, Kerala, India.
[3] Assistant Professor, Department of Pharmacy Practice, Ezhuthachan College of Pharmaceutical Sciences, Marayamuttom, Thiruvananthapuram, Kerala, India.
[4] Consultant Surgical Oncologist at NIMS Medicity (Noorul Islam Multi-Speciality Hospital) in Aralummoodu, Neyyattinkara, Thiruvananthapuram, Kerala, India.
[5] Principal/HOD, Department of Pharmacy Practice, Ezhuthachan College of Pharmaceutical Sciences, Marayamuttom, Thiruvananthapuram, Kerala, India.

ARTICLE INFO

Published: 25 Nov 2026
Keywords:
Penile cancer, squamous cell carcinoma, condyloma acuminatum, balanitis xerotica obliterans, lymphovascular invasion, partial penectomy, penile foreskin
DOI:
10.5281/zenodo.24527253

ABSTRACT

Penile cancer is uncommon, and it mostly occurs as squamous cell carcinoma (SCC). It appears as ulcerated or enlarging lesions, phimosis, and persistent inflammatory changes in the penis. The risk factors associated with penile cancer are HPV infection, chronic inflammation, phimosis, and lichen sclerosis. The co-existence of invasive penile squamous cell carcinoma and condyloma acuminatum is an important clinical feature. A man with the age of 34years old came to the hospital with a symptom of inability to retract the foreskin of the penis along with a thickening of the skin and a whitish discharge from the penis. The patient was diagnosed with balanitis xerotica obliterans (BXO) and was subjected to a surgery for the removal of the foreskin. The biopsy taken from the ulcer was indicating that he may be suffering from squamous cell carcinoma, which led to the referral to the department of surgical oncology. Upon clinical examination, there was a lesion seen which was more like an ulcer, affecting the glans penis and extending towards the base of the penis along with enlarged inguinal lymph node on the right side. The imaging test carried out showed the swollen and enlarged penis along with a suspicious right inguinal lymph node. The patient went under a surgery for partial penectomy, regional lymph node dissection, excision of the wart and

***Corresponding Author:** Vibisha Victor
Address: Pharm D Interns, Ezhuthachan College of Pharmaceutical Sciences, Marayamuttom, Thiruvananthapuram, Kerala, India.
Email ✉: vibishavictor01@gmail.com

Relevant conflicts of interest/financial disclosures: The authors declare that the research was conducted in the absence of any commercial or financial relationships that could be construed as a potential conflict of interest.

the use of frozen section biopsy for assessment.The final histopathological evaluation confirmed a diagnosis of moderately differentiated (Grade 2) squamous cell carcinoma, not otherwise specified (NOS) with lamina propria invasion and lymphovascular invasion. Perineural invasion was absent and all surgical margins were free of invasive carcinoma. The lymph nodes are examined, eight showed reactive changes without evidence of metastasis. Separate lesion in the penile foreskin was diagnosed as condyloma acuminatum with no signs of dysplasia or malignancy. The pathological stage indicates pT1b N0. Significance of early biopsy and histopathological assessment of persistent penile lesions is highlighted in this case, especially in patients with phimosis and chronic inflammation. Detection of SCC as well as condyloma acuminatum shows the necessity to approach separate penile lesions independently. Although lymph nodes are free and surgical margins also show freedom from carcinoma, presence of lymphovascular invasion implicates risk of regional recurrence, thereby underlining importance of continued oncological follow-up.

INTRODUCTION

Penile cancer is a rare type of cancer around the world but the rate of incidence varies from place to place. The most common type is the squamous cell carcinoma (SCC), which accounts for more than 95% of the cases of cancer among males. The majority of cases originates from the epithelial lining of either the glans penis or the inner prepuce. The disease can initially present with signs that can be very vague, including a non-healing ulcer, an inflammatory or proliferative lesion, swelling of the penis, discharge, or phimosis. The disease can often be mistaken for a benign type of inflammation or infection leading to diagnosis delays [1,2,3].

The emergence of penile squamous cell carcinoma (SCC) has been linked to a number of factors, including persistent infection with the human papillomavirus (HPV), phimosis, chronic inflammation, smoking, and lichen sclerosis, also referred to as balanitis xerotica obliterans. Chronic inflammation may cause cancer by leading to epithelial damage and alterations in the tissues. Nevertheless, the exact mechanisms underlying HPV-independent carcinogenic processes remain uncertain [1,4,5].

Condyloma acuminatum, or simply genital warts, is a benign growth that is caused by HPV types known to be low-risk, especially HPV type 6 and HPV type 11. This type of lesion can be recognized by its histological characteristics, including the formation of papillae, thickening of the epithelium, and the presence of koilocytic changes. While condyloma acuminatum is not considered a harmful growth by itself, its presence should still prompt careful evaluation of the condition by the medical professionals as it is found in association with penile cancer [6,7].

The way penile SCC is diagnosed is through histopathological examination of a biopsy. Other procedures include determining the status of the primary tumor, lymph nodes, and possible distant metastasis. Important prognostic factors in the diagnosis of penile SCC are the histological grade and level of invasion, lymphatic invasion, perineural invasion, and lymph node status [1,2,8].

This case presents a man in his mid-thirties who had the diagnosis of BXO and was found to have moderately differentiated penile SCC and separate condyloma acuminatum lesion of the penile foreskin. The importance of biopsy and histological evaluation is highlighted here.

CASE PRESENTATION

A 34-year-old man came to the General Surgery department with complaints of phimosis, associated with thickened prepuce, and whitish discharge. Clinical evaluation led to the diagnosis of balanitis xerotica obliterans.

A week later, the patient underwent the excision of the preputial skin along with the biopsy of the ulcer-edges under the local anesthesia. Intraoperatively thickened preputial skin was noted and also the presence of an ulcer formed on the top of the penis.

After the biopsy was done, the findings were suggestive of squamous cell carcinoma. Based on these findings patient was referred to the department of surgical oncology for further management.

During the later assessment, a localized examination showed an ulcerative tumor affecting the penis glans, causing swelling towards the base of the penis. The patient had had a circumcision in the past. The patient had a swollen right groin lymph node, while there was no detectable swelling in the left groin lymph node.

The patient was awake, alert, and not feverish. The patient's vital signs were normal, with a heart rate of 62 beats/min, blood pressure of 130/70 mmHg, a respiratory rate of 20 breaths/min, and an oxygen saturation level of 98%.

No significant abnormalities were found during the systemic investigation. The patient has no known pre-existing medical conditions.

As part of the initial staging workup, a contrast-enhanced abdominal and CT scan was obtained.

The results showed considerable thickening with heterogeneous enhancement, affecting mainly the anterior aspect of the penis, which confirmed the existence of the previously known primary lesion. There was a noteworthy right inguinal node presenting homogeneous enhancement and being rounded in shape, thus leading to suspicion of possible regional lymph nodes involvement due to this anatomical location and structure.

No considerable pelvic or retroperitoneal lymph nodes enlargement could be seen.

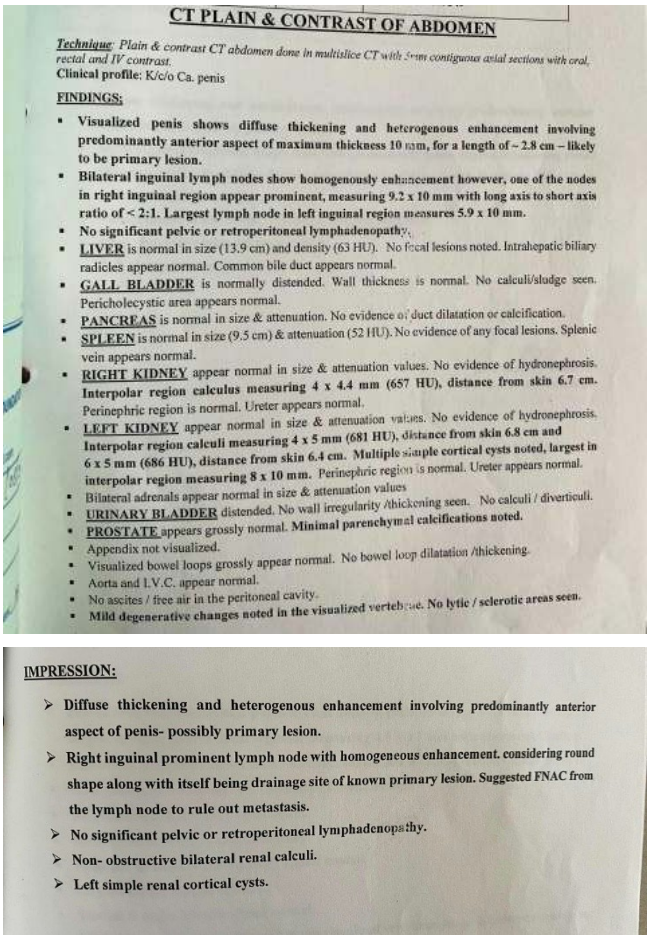

CT PLAIN & CONTRAST OF ABDOMEN

Technique: *Plain & contrast CT abdomen done in multislice CT with 5mm contiguous axial sections with oral, rectal and IV contrast.*

Clinical profile: K/c/o Ca. penis

FINDINGS:

- **Visualized penis shows diffuse thickening and heterogenous enhancement involving predominantly anterior aspect of maximum thickness 10 mm, for a length of ~ 2.8 cm – likely to be primary lesion.**
- **Bilateral inguinal lymph nodes show homogenously enhancement however, one of the nodes in right inguinal region appear prominent, measuring 9.2 x 10 mm with long axis to short axis ratio of < 2:1. Largest lymph node in left inguinal region measures 5.9 x 10 mm.**
- **No significant pelvic or retroperitoneal lymphadenopathy.**
- **LIVER** is normal in size (13.9 cm) and density (63 HU). No focal lesions noted. Intrahepatic biliary radicles appear normal. Common bile duct appears normal.
- **GALL BLADDER** is normally distended. Wall thickness is normal. No calculi/sludge seen. Pericholecystic area appears normal.
- **PANCREAS** is normal in size & attenuation. No evidence of duct dilatation or calcification.
- **SPLEEN** is normal in size (9.5 cm) & attenuation (52 HU). No evidence of any focal lesions. Splenic vein appears normal.
- **RIGHT KIDNEY** appear normal in size & attenuation values. No evidence of hydronephrosis. **Interpolar region calculus measuring 4 x 4.4 mm (657 HU), distance from skin 6.7 cm.** Perinephric region is normal. Ureter appears normal.
- **LEFT KIDNEY** appear normal in size & attenuation values. No evidence of hydronephrosis. **Interpolar region calculi measuring 4 x 5 mm (681 HU), distance from skin 6.8 cm and 6 x 5 mm (686 HU), distance from skin 6.4 cm. Multiple simple cortical cysts noted, largest in interpolar region measuring 8 x 10 mm.** Perinephric region is normal. Ureter appears normal.
- Bilateral adrenals appear normal in size & attenuation values
- **URINARY BLADDER** distended. No wall irregularity /thickening seen. No calculi / diverticuli.
- **PROSTATE** appears grossly normal. **Minimal parenchymal calcifications noted.**
- Appendix not visualized.
- Visualized bowel loops grossly appear normal. No bowel loop dilatation /thickening.
- Aorta and I.V.C. appear normal.
- No ascites / free air in the peritoneal cavity.
- **Mild degenerative changes noted in the visualized vertebrae. No lytic / sclerotic areas seen.**

IMPRESSION:

- **Diffuse thickening and heterogenous enhancement involving predominantly anterior aspect of penis- possibly primary lesion.**
- **Right inguinal prominent lymph node with homogeneous enhancement. considering round shape along with itself being drainage site of known primary lesion. Suggested FNAC from the lymph node to rule out metastasis.**
- **No significant pelvic or retroperitoneal lymphadenopathy.**
- **Non- obstructive bilateral renal calculi.**
- **Left simple renal cortical cysts.**

Figure 1: ***CT Plain & Contrast of Abdomen***

CECT of the thorax displayed multiple sub fissural and parenchymal nodules involving bilateral lower lobes, which were found earlier during staging evaluation for metastasis confirmation.The available medical records do not confirm the status of those formations.

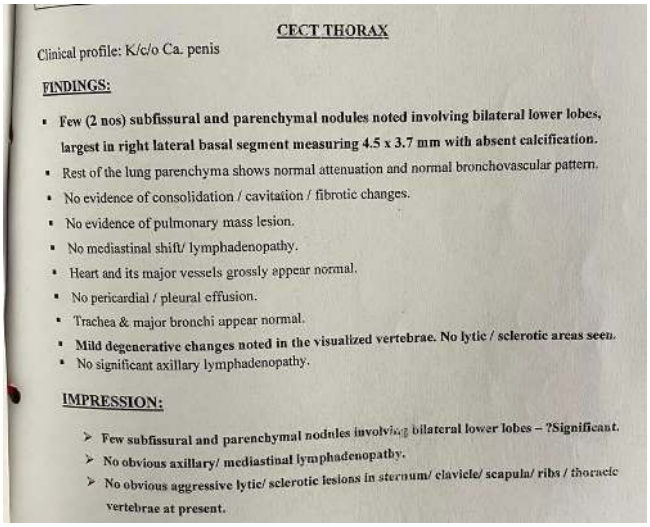

CECT THORAX

Clinical profile: K/c/o Ca. penis

FINDINGS:

- Few (2 nos) subfissural and parenchymal nodules noted involving bilateral lower lobes, largest in right lateral basal segment measuring 4.5 x 3.7 mm with absent calcification.
- Rest of the lung parenchyma shows normal attenuation and normal bronchovascular pattern.
- No evidence of consolidation / cavitation / fibrotic changes.
- No evidence of pulmonary mass lesion.
- No mediastinal shift/ lymphadenopathy.
- Heart and its major vessels grossly appear normal.
- No pericardial / pleural effusion.
- Trachea & major bronchi appear normal.
- Mild degenerative changes noted in the visualized vertebrae. No lytic / sclerotic areas seen.
- No significant axillary lymphadenopathy.

IMPRESSION:

- Few subfissural and parenchymal nodules involving bilateral lower lobes – ?Significant.
- No obvious axillary/ mediastinal lymphadenopathy.
- No obvious aggressive lytic/ sclerotic lesions in sternum/ clavicle/ scapula/ ribs / thoracic vertebrae at present.

Figure 2: ***CECT Thorax***

After further discussions, the definitive surgical approach has been established.

The surgery was performed on the patient on August 7, 2026, while he was under general anesthesia.

The procedures performed during the operation included partial penectomy, right ilioinguinal lymph node dissection, left superficial inguinal lymph node dissection, excision of the verrucous growth on the shaft of the penis, and an intraoperative frozen-section examination.

The findings during the operation were those related to the presence of an ulcer proliferative mass in the area of the glans penis, enlarged lymph nodes in the right superficial inguinal area, and the presence of a verrucous growth on the shaft of the penis.

The procedure was carried out successfully and bilateral inguinal drains were placed for post-operative drainage purposes: one was placed on each side of the body.

The size of the resected specimen after a partial penectomy was 4.5 × 1.0 × 3.5 cm. The patient's case showed the development of an ulcerated mass 2.5 × 2.3 cm in the glans penis.

Histopathological examination showed the presence of an infiltrative tumor consisting of squamous cells with a diffuse arrangement, islands, and nests. The tumor cells showed moderate levels of pleomorphism as well as an increased nuclear/cytoplasmic ratio, irregular nuclear boundary, clumped chromatin, and eosinophilic cytoplasm with signs of dyskeratosis.

The stroma around the tumor was characterized by desmoplastic changes accompanied by moderate infiltration by lymphocytes.

The most important pathological findings are as follows: Histological diagnosis: squamous cell carcinoma, grade of differentiation: grade II or moderately differentiated squamous carcinoma, tumor spread: tumor infiltration of the submucosa, lymphovascular invasion: present, perineural invasion: absent, involvement of corpus spongiosum and corpora cavernosa: absent, histopathological findings from the resection margins: urethral, periurethral, corpora cavernosa, Buck's fascia and skin.

The lymph nodes that were examined did not show any signs of cancer.

- The right inguinal lymph nodes showed no signs of cancer in any of the three samples.
- The right iliac lymph nodes had no positive cancer samples in any of the five samples taken.

Therefore, all eight samples examined for cancer showed none to be present.

The penile foreskin that was examined showed signs of thickening of the skin that had many levels of keratin in it.

The changes in certain cells also means that they are infected by the virus.

There was also some inflammation in the area where the foreskin connects to the penile shaft where there is increased number of immune cells.

Most importantly, none of the samples were showing presence of any abnormal cells that can turn cancerous.

Thus, the final report was ccondyloma acuminatum (genital wart) of the penile foreskin.

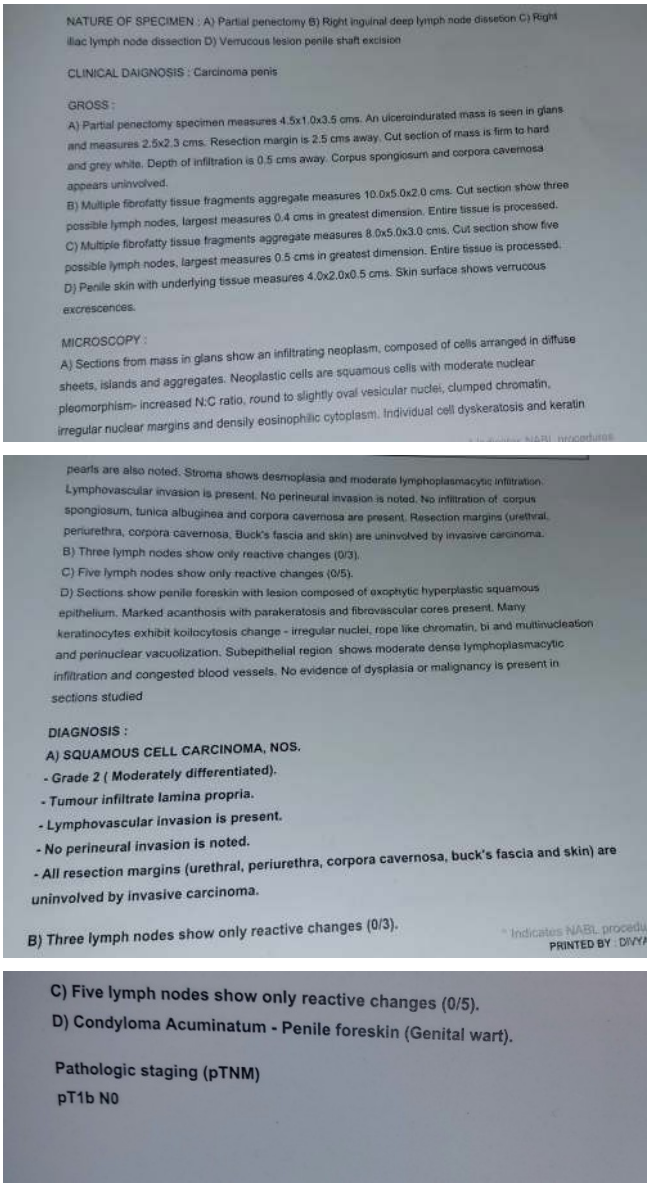

NATURE OF SPECIMEN : A) Partial penectomy B) Right inguinal deep lymph node dissetion C) Right iliac lymph node dissection D) Verrucous lesion penile shaft excision

CLINICAL DAIGNOSIS : Carcinoma penis

GROSS :

A) Partial penectomy specimen measures 4.5x1.0x3.5 cms. An ulceroindurated mass is seen in glans and measures 2.5x2.3 cms. Resection margin is 2.5 cms away. Cut section of mass is firm to hard and grey white. Depth of infiltration is 0.5 cms away. Corpus spongiosum and corpora cavernosa appears uninvolved.

B) Multiple fibrofatty tissue fragments aggregate measures 10.0x5.0x2.0 cms. Cut section show three possible lymph nodes, largest measures 0.4 cms in greatest dimension. Entire tissue is processed.

C) Multiple fibrofatty tissue fragments aggregate measures 8.0x5.0x3.0 cms. Cut section show five possible lymph nodes, largest measures 0.5 cms in greatest dimension. Entire tissue is processed.

D) Penile skin with underlying tissue measures 4.0x2.0x0.5 cms. Skin surface shows verrucous excrescences.

MICROSCOPY :

A) Sections from mass in glans show an infiltrating neoplasm, composed of cells arranged in diffuse sheets, islands and aggregates. Neoplastic cells are squamous cells with moderate nuclear pleomorphism- increased N:C ratio, round to slightly oval vesicular nuclei, clumped chromatin, irregular nuclear margins and densily eosinophilic cytoplasm. Individual cell dyskeratosis and keratin pearls are also noted. Stroma shows desmoplasia and moderate lymphoplasmacytic infiltration. Lymphovascular invasion is present. No perineural invasion is noted. No infiltration of corpus spongiosum, tunica albuginea and corpora cavernosa are present. Resection margins (urethral, periurethra, corpora cavernosa, Buck's fascia and skin) are uninvolved by invasive carcinoma.

B) Three lymph nodes show only reactive changes (0/3).

C) Five lymph nodes show only reactive changes (0/5).

D) Sections show penile foreskin with lesion composed of exophytic hyperplastic squamous epithelium. Marked acanthosis with parakeratosis and fibrovascular cores present. Many keratinocytes exhibit koilocytosis change - irregular nuclei, rope like chromatin, bi and multinucleation and perinuclear vacuolization. Subepithelial region shows moderate dense lymphoplasmacytic infiltration and congested blood vessels. No evidence of dysplasia or malignancy is present in sections studied

DIAGNOSIS :

A) SQUAMOUS CELL CARCINOMA, NOS.

- Grade 2 (Moderately differentiated).

- Tumour infiltrate lamina propria.

- Lymphovascular invasion is present.

- No perineural invasion is noted.

- All resection margins (urethral, periurethra, corpora cavernosa, buck's fascia and skin) are uninvolved by invasive carcinoma.

B) Three lymph nodes show only reactive changes (0/3).

* Indicates NABL procedu

PRINTED BY : DIVY

C) Five lymph nodes show only reactive changes (0/5).

D) Condyloma Acuminatum - Penile foreskin (Genital wart).

Pathologic staging (pTNM)

pT1b N0

Figure 3: *Histopathology Report*

After surgery, the patient was moved from the operating room to recovery and then to a surgical ward for observation. The patient was given the necessary medications, fluids, care of the wounds and prevention of blood clots in a timely manner.

The condition of the wound was checked continuously and found to be acceptable. Amount of output from the drain into the body was observed carefully. The left drain was removed after 5 days of surgery on account of its low output. The right drain remained intact and functional.

The patient gradually started eating and moving about as he was able to do so. His bodily functions were normal and other problems did not arise during the period of treatment.

The surgically removed organs, growth and lymph nodes from the area were sent to the lab for further investigation.

Both patient and family were briefed about the treatment, advice on use of a drain and what to look out for when seeking medical help.

DISCUSSION

The malignant tumor known as penile squamous cell carcinoma is uncommon and has properties that may initially make it look like some other benign status such as inflammation or infection. The unique aspect is that this particular case involves a man with confirmed diagnosis of three distinct conditions. These conditions are chronic balanitis xerotica obliterans, moderately differentiated invasive penile squamous cell carcinoma, and condyloma acuminatum affecting the foreskin of the same penis.

Thus, the diagnosis of SCC was considered to be highly likely due to the presence of the ulcer during the investigation for and treatment of phimosis. Confirmation of the diagnosis was achieved through histopathological examination which shows that careful treatment in case of persistent lesions should be always carried out instead of resorting to the notion of inflammatory disease.

The genital presentation of lichen sclerosus, a chronic inflammatory skin condition that usually affects the prepuce and glans penis, is known as Balanitis xerotica obliterans. Symptoms include scarring, thickening of the prepuce, phimosis, pain, and inability to retract the prepuce.

Studies have shown that inflammation and repetitive injuries of epithelial tissue might be blamed for the occurrence of penile cancer unrelated to HPV infection. Various authors have confirmed a link between histologically diagnosed genital type of lichen sclerosus and the occurrence of penile SCC [1,4].

Herein, the patient was diagnosed with Balanitis xerotica obliterans with phimosis and the presence of the abnormal discharge. Examinations that followed identified an ulcer with the indurated part of the penis. Histological analysis indicated the occurrence of squamous cell carcinoma.

The clinical developments in this case indicate the necessity to constantly monitor the risk of malignancy in all patients suffering from chronic inflammatory disorders of the penis, especially, when there are ulcerations or proliferating lesions visible. However, the documents referred do not prove histological connection between the BXO and the present carcinoma and therefore a direct cause-effect relationship cannot be proven in this case.

Condyloma acuminatum is a benign epithelial proliferation predominantly associated with low-risk HPV genotypes, especially HPV-6 and HPV-11. Histologically, it is characterised by papillomatous epithelial growth, acanthosis, hyperkeratosis or parakeratosis and koilocytotic changes.

In the present case, the separately excised verrucous lesion demonstrated marked acanthosis, parakeratosis, fibrovascular cores and koilocytotic changes. No epithelial dysplasia or invasive malignancy was identified. These findings supported the diagnosis of condyloma acuminatum.

In contrast, the primary glans lesion showed infiltrating malignant squamous cells with moderate differentiation, nuclear pleomorphism, dyskeratosis and keratin pearl formation.

The distinction between these two lesions is clinically important because a verrucous or wart-like appearance does not necessarily indicate benign disease. Both lesions require appropriate histopathological evaluation when their clinical characteristics are suspicious.

Mannam et al. (2024) discussed the relationship between HPV infection and penile cancer, highlighting the involvement of HPV in a proportion of penile malignancies and the differences between HPV-associated and HPV-independent tumour pathways [6].

Similarly, Olesen et al. (2019), in their systematic review and meta-analysis, reported an overall HPV DNA prevalence of approximately 50.8% in penile cancer. The prevalence varied considerably according to histological subtype [7].

In the current case, condyloma acuminatum was confirmed histologically; however, HPV genotyping and p16 immunohistochemistry were not documented. Therefore, it is not possible to establish whether the invasive SCC was HPV-associated or HPV-independent. The coexistence of the two lesions should not be

interpreted as evidence that the genital wart progressed into invasive carcinoma.

Histopathological examination is important to understand the biological characteristics and survival outcome of penile SCC. Among the important parameters are tumour differentiations, level of invasion, lymphovascular invasion, perineural invasion, and surgical margin status.

This case shows moderately differentiated SCC (Grade 2) with tumour induration extending up to lamina propria. Lymphovascular invasion is present, while perineural invasion is absent.

TNM classification classifies tumours that invade subepithelial connective tissue as T1. The inclusion of lymphovascular or perineural invasion or poor differentiation places tumour under category T1b [1,9].

Thus, the pathology classification of pT1b in this patient matches with the manifestation of lymphovascular invasion.

Jannello et al. (2025) evaluated the prognostic significance of lymphovascular invasion in penile SCC using a large retrospective cohort. Their findings demonstrated that LVI was independently associated with an increased likelihood of lymph node invasion. Patients with LVI had a higher frequency of lymph node involvement than those without it [8].

In the current case, this important pathological risk factor was noted, even when no metastatic deposits were found in any of the eight lymph nodes evaluated. This shows that LVI is an indicator of risk and not a sign of lymph node metastasis.

Another positive finding was the absence of tumor infiltration into the surgical margins assessed. The corpus spongiosum and cavernous bodies were also free of manifestations of the presence of tumor, indicating that the tumor did not extend beyond the superficial support tissues into the erectile tissues.

Brouwer et al (2023) emphasized histopathological confirmation, appropriate primary tumor treatment and timely lymph node staging [2]. This case the patient underwent biopsy definite surgery and regional lymph node assessment.

Over all the current case reinforces the value of integrating the clinical examination with radiological and histopathological findings in the management of penile malignancy. It also serves to illustrate why a separate verrucous lesion should not be assumed to be part of the primary carcinoma.

CONCLUSION

The current case indicates the occurrence of moderately differentiated squamous cell carcinoma of the penis in combination with condyloma acuminatum of the foreskin in a 34-year-old male with a known history of balanitis xerotica obliterans diagnosis. The presenting complaint of phimosis, thicker preputial skin, and a white discharge demonstrate the way how penile malignancy might have the features of a benign inflammatory disease at first glance. However, the following biopsy played a critical role in the diagnosis establishment and subsequent surgical management.

The definitive histopathological examination revealed Grade 2 SCC with lamina propria invasion, lymphovascular invasion, and showed pT1bN0 characteristics. It was indicated that all surgical margins were negative for the presence of any invasive carcinoma and eight examined lymph nodes were negative for metastasis. In turn, the separated lesion was identified as condyloma acuminatum with no dysplasia or malignancy.

The case illustrates the necessity of conducting biopsy at an early stage, properly conducting histopathological diagnosis of penile lesions, and accurately evaluating lymph nodes. Moreover, it makes it clear that while condyloma is detected, it gives no information about the HPV status or mechanism involved in the development of the underlying invasive carcinoma.

Though the early recovery is satisfactory, lymphovascular invasion necessitates due diligence about long-term oncological follow-up and multidisciplinary therapy.

REFERENCES

1. European Association of Urology. EAU-ASCO guidelines on penile cancer. Arnhem: European Association of Urology; 2026.
2. Brouwer OR, Albersen M, Parnham A, Protzel C, Pettaway CA, Ayres B, et al. European Association of Urology-American Society of Clinical

Oncology Collaborative Guideline on Penile Cancer: 2023 Update. Eur Urol. 2023;83 (6):548-560.

3. ESMO-EURACAN. Penile cancer: ESMO-EURACAN Clinical Practice Guideline for diagnosis, treatment and follow-up. ESMO Open. 2024;9 (7):103481.
4. Lewis FM, Tatnall FM, Velangi SS, Bunker CB, Kumar A, Brackenbury F, et al. British Association of Dermatologists guidelines for the management of lichen sclerosus, 2018. Br J Dermatol. 2018;178 (4):839-853.
5. Weigand DA. Lichen sclerosus et atrophicus, multiple dysplastic keratoses, and squamous-cell carcinoma of the glans penis. J Dermatol Surg Oncol. 1980;6 (1):45-50.
6. Mannam G, Miller JW, Johnson JS, Gullapalli K, Fazili A, Spiess PE, et al. HPV and penile cancer: epidemiology, risk factors, and clinical insights. Pathogens. 2024;13 (9):809.
7. Olesen TB, Sand FL, Rasmussen CL, Albieri V, Toft BG, Norrild B, et al. Prevalence of human papillomavirus DNA and p16INK4a in penile cancer and penile intraepithelial neoplasia: a systematic review and meta-analysis. Lancet Oncol. 2019;20 (1):145-158.
8. Jannello LM, De Angelis M, Siech C, Di Bello F, Rodriguez Peñaranda N, Tian Z, et al. Validation of lymphovascular invasion as a predictor of lymph-node invasion in squamous cell carcinoma of the penis. Minerva Urol Nephrol. 2025;77 (2):226-232.
9. Amin MB, Edge SB, Greene FL, Byrd DR, Brookland RK, Washington MK, et al., editors. AJCC Cancer Staging Manual. 8th ed. New York: Springer; 2017.
10. International Collaboration on Cancer Reporting. Carcinoma of the penis and distal urethra: histopathology reporting guide. 2nd ed. Sydney: ICCR; 2024.
11. WHO Classification of Tumours Editorial Board. Urinary and male genital tumours. 5th ed. Lyon: International Agency for Research on Cancer; 2022.
12. National Cancer Institute. Penile cancer treatment (PDQ): health professional version. Bethesda (MD): National Cancer Institute.
13. Bruni L, Albero G, Serrano B, Mena M, Gómez D, Muñoz J, et al. Global and regional estimates of genital human papillomavirus prevalence among men: a systematic review and meta-analysis. Lancet Glob Health. 2023;11 (9):e1345-e1362.
14. Daling JR, Madeleine MM, Johnson LG, Schwartz SM, Shera KA, Wurscher MA, et al. Penile cancer: importance of circumcision, human papillomavirus and smoking in in situ and invasive disease. Int J Cancer. 2005;116 (4):606-616.
15. Maden C, Sherman KJ, Beckmann AM, Hislop TG, Teh CZ, Ashley RL, et al. History of circumcision, medical conditions, and sexual activity and risk of penile cancer. J Natl Cancer Inst. 1993;85 (1):19-24.
16. Hakenberg OW, Comperat EM, Minhas S, Necchi A, Protzel C, Watkin P. EAU guidelines on penile cancer: 2014 update. Eur Urol. 2015;67 (1):142-150.

HOW TO CITE: Vibisha Victor, Darsana Radhika, Drishya L., G. S. Jeevan, Shaiju Dharan, Coexisting Penile Squamous Cell Carcinoma and Condyloma Acuminatum of the Penile Foreskin in a Young Adult with Balanitis Xerotica Obliterans: A Case Report, Int. J. of Pharm. Sci., 2026, Vol 4, Issue 11, 4541-4548. https://doi.org/10.5281/zenodo.24527253