



**INTERNATIONAL JOURNAL OF
PHARMACEUTICAL SCIENCES**
[ISSN: 0975-4725; CODEN(USA): IJPS00]
Journal Homepage: <https://www.ijpsjournal.com>



Research Article

Gastroprotective potential of Agropyren repen in Indomethacin inducing ulcer in experimental animal

Urwela Sahare*, J. V. Vyas

Department of Pharmacology, Vidyabharati college of pharmacy, Sant Gadge Baba Amravati University, Camp Road, 444602, Maharashtra India

ARTICLE INFO

Published: 19 Jun. 2026

Keywords:

Agropyron repens ,Peptic Ulcer Disease, Gastroprotective activity, Indomethacin-induced ulcer ,Omeprazole, Ethnomedicine, Antisecretory, Phytochemicals

DOI:

10.5281/zenodo.20757186

ABSTRACT

Peptic Ulcer Disease (PUD) remains a global health challenge, primarily driven by Helicobacter pylori infection and the widespread use of Nonsteroidal Anti-inflammatory Drugs (NSAIDs). Agropyron repens (Couch Grass) has a long history in traditional medicine for urinary ailments, but its gastroprotective potential has not been extensively explored. This study aimed to evaluate the anti-ulcer activity of the whole plant ethanolic extract of Agropyron repens against indomethacin-induced gastric ulcers in Swiss Wistar rats. Thirty rats were divided into five groups: Control, Negative Control (Indomethacin 30 mg/kg), Standard (Omeprazole 20 mg/kg), and two treatment groups receiving ethanolic extract of A. repens (250 mg/kg and 500 mg/kg). Parameters including ulcer index, gastric pH, gastric volume, free acidity, and total acidity were measured. Histopathological examinations were conducted to assess mucosal integrity. Pretreatment with A. repens extract showed a significant ($p < 0.001$) dose-dependent protection against gastric lesions. The high-dose group (500 mg/kg) exhibited an 82% protection rate, significantly reducing the ulcer index from 17.73 in the control group to 3.19. Furthermore, the extract significantly increased gastric pH (3.15 vs. 1.5 in the control) and reduced total acidity and gastric volume. Histopathology confirmed that the 500 mg/kg dose prevented deep ulceration and maintained the mucosal lining, comparable to the effects of Omeprazole (85% protection). The ethanolic extract of Agropyron repens possesses potent anti-ulcer and antisecretory activity. This gastroprotective effect is likely attributed to the presence of bioactive secondary metabolites such as flavonoids, phenols, and tannins, which enhance mucosal defense mechanisms.

*Corresponding Author: Urwela Sahare

Address: Department of Pharmacology, Vidyabharati college of pharmacy, Sant Gadge Baba Amravati University, Camp Road, 444602, Maharashtra India

Email ✉: urwela160802@gmail.com

Relevant conflicts of interest/financial disclosures: The authors declare that the research was conducted in the absence of any commercial or financial relationships that could be construed as a potential conflict of interest.



INTRODUCTION

Peptic ulcer disease (PUD) represents a significant global health burden, historically characterized as a chronic, relapsing condition that once carried high rates of morbidity and mortality. It is defined as a deep, circumscribed destruction of the gastrointestinal mucosa—specifically the stomach (gastric ulcer) or the first part of the small intestine (duodenal ulcer)—that penetrates through the mucosal lining, often reaching the muscularis propria. While the incidence of PUD has decreased remarkably in recent decades due to better understanding and treatment, it still affects approximately 5% to 10% of the world's population at some point during their lifetime. The conceptualization of peptic ulcers underwent a paradigm shift in 1982 when Warren and Marshall identified *Helicobacter pylori* (*H. pylori*). This discovery moved the medical consensus from an “acid-driven” dogma to an infectious disease model. Currently, the two most prominent causes of PUD are chronic infection with *H. pylori* and the widespread use of Nonsteroidal Anti-inflammatory Drugs (NSAIDs), including acetylsalicylic acid (aspirin). These factors account for the vast majority of cases, while less common causes—such as Zollinger-Ellison syndrome (a gastrin-secreting neuroendocrine tumor), Crohn's disease, and viral infections—represent fewer than 5% of diagnoses (1 -8). The development of an ulcer is essentially the result of a physiological imbalance between “offensive” and “defensive” factors within the gastroduodenal environment. Under normal circumstances, the stomach and duodenal linings are protected by a robust defense system consisting of the mucus-bicarbonate barrier: A physical and chemical shield that neutralizes acid. Prostaglandins (specifically PGE₂): These lipids stimulate cell proliferation, mucus secretion, and maintain mucosal blood flow. Nitric Oxide (NO): Works

alongside prostaglandins to ensure adequate perfusion, delivering oxygen while removing toxic metabolites. When *H. pylori* infects the mucosa, it triggers an inflammatory response involving neutrophils and lymphocytes, leading to epithelial cell damage. The bacteria's urease activity produces ammonia, which neutralizes local acidity but also creates a toxic environment that disrupts the regulatory feedback of gastrin, leading to hyperchlorhydria (excess acid). Conversely, NSAIDs cause damage by inhibiting the cyclooxygenase (COX) enzymes, thereby depleting the intracellular concentration of protective prostaglandins. This systemic inhibition impairs the integrity of the mucosal barrier and reduces blood flow, making the tissue highly susceptible to acid-induced erosion (9-12). The hallmark symptom of PUD is epigastric pain, often described as a burning or “gnawing” sensation. Duodenal Ulcers: Classically present with pain during fasting states or at night, typically relieved by food intake or antacids. Gastric Ulcers: Pain often occurs shortly after eating and may not be relieved by food, sometimes leading to weight loss due to food avoidance. (13). Diagnosis is primarily achieved through upper gastrointestinal endoscopy, which allows for direct visualization of the ulcer and the collection of mucosal biopsies. Biopsies are critical for ruling out malignancy—particularly in gastric ulcers—and for confirming the presence of *H. pylori* through histological examination or rapid urease tests. Non-invasive methods, such as the ¹³C-urea breath test or stool antigen tests, are also highly effective for detecting infection. (14) Modern management focuses on the “triple aim” of relieving pain, healing the lesion, and preventing recurrence. Eradication therapy: For *H. pylori*-positive patients, standard first-line treatment involves “triple therapy”: a combination of a Proton Pump Inhibitor (PPI) and



two antibiotics (usually amoxicillin and clarithromycin) for 7 to 14 days. Due to rising antibiotic resistance, quadruple therapies involving bismuth or sequential regimens are increasingly employed. (15) Acid Suppression: PPIs have become the gold standard for healing because they irreversibly bind to the H⁺ /K⁺ -ATPase pump in parietal cells, providing more potent acid inhibition than older H₂-receptor antagonists. (16) Preventative Measures: Patients requiring long-term NSAID therapy may be prescribed “gastroprotective” agents like misoprostol or switched to COX-2 selective inhibitors to minimize the risk of secondary ulcers. Agropyron repens is a perennial rhizomatous plant native to temperate Europe and Central Asia. It is recognized by several synonyms, including Elytrigia repens and Triticum repens. Historically, it has served as a critical medicinal resource, particularly for urinary tract ailments. Traditional applications utilize its rhizomes, roots, and seeds as a soothing diuretic and demulcent to alleviate pain and spasms associated with cystitis, urethritis, and prostatitis. The therapeutic efficacy of A. repens is attributed to its diverse chemical constituents: Primary Metabolites: The plant is rich in carbohydrates (including tritacin and mannitol), mucilaginous substances, and pectin. Secondary Metabolites: It contains flavonoids, saponins, phenol compounds (such as p-coumaric and chlorogenic acids), and essential oils composed of monoterpenes like carvacrol and thymol. Mineral Content: It is notable for high concentrations of silica, iron, and potassium. Scientific investigations have validated several key pharmacological effects: Metabolic Regulation: Aqueous extracts demonstrate significant hypoglycemic and hypolipidemic properties. In diabetic rat models, single and repeated oral administration successfully normalized blood glucose and significantly reduced plasma cholesterol and triglyceride levels.

Anti-inflammatory Action: Ethanol extracts show moderate inhibition of edema, while topical applications in cream form have proven comparable to standard glucocorticoids in treating allergic contact dermatitis, significantly accelerating skin recovery. Urological Support: The high mannitol content acts as an osmotic diuretic. Clinical trials indicate that fluid extracts significantly reduce symptoms of urge incontinence, dysuria, and nycturia in patients with urinary tract infections or prostate disorders

Materials and Methods

2.1. Preliminary Phytochemical Screening

The ethanolic extract was subjected to qualitative phytochemical analysis to identify the presence of major secondary metabolites, including alkaloids, flavonoids, glycosides, phenolic compounds, sterols, saponins, carbohydrates, and amino acids, using standard phytochemical screening procedures.

2.2 Experimental Animals

Adult Swiss Wistar rats of either sex, weighing 220–270 g, were obtained from the Animal House Facility of Vidyabharati College of Pharmacy, Amravati. The animals were housed in polypropylene cages under controlled environmental conditions (24–27°C temperature, 60–65% relative humidity, and a 12 h light/dark cycle). Prior to experimentation, they were acclimatized for one week and provided with standard pellet diet and drinking water ad libitum. All experimental procedures were conducted in accordance with CPCSEA guidelines and were approved by the Institutional Animal Ethics Committee (IAEC). (18-19)

2.3 Chemical



Omeprazole (20 mg/kg), Indomethacin (30mg/kg), Phenolphthalein, Topfer's reagent, Ethanolic extract of Agropyran repen

1	Spot ulcer
1.5	Hemorrhagic streak
2	Deep ulcer
3	Perforation

2.4 Experimental design

A total 30 Swiss Wister rats of either sex were randomly divided into five groups 6 animals were allocated to each group and were kept in experimental period of 8 days , as follows.

Group I (Control)

Animals should administrated with 0.9% NaCl solution at 0.5 ml/rat with normal diet.

Group II (Negative control)

Indomethacin 30 mg/kg (p.o.) dissolved in the vehicle alone on the 8th day of Experiment and administrated to animal, which kept prior fasting of 24 hrs

Group III (Standard control)

It serving as positive control received omeprazole (20 mg/kg) for 7days and on 8th day indomethacin is administrated prior fasting of 24 hrs

Group IV (Low dose)

Animals received Agropyren repen extract (250mg/kg) BW, p.o. dissolved in the water for 7 day and than indomethacin on 8th day

Group V (High dose)

Animals received Agropyren repen extract (500mg/kg) BW, p.o. dissolved in the water for 7 day and than indomethacin on 8th day

2.5. Scoring of the ulcer

Score	Observation
0	No ulcer
0.5	Redness

The mean ulcer score for each animal gives the ulcer index value.

Estimation of Gastric pH:

The pH of gastric content which was collected earlier can be determined by the digital pH meter [20].

Determination of Free and Total Acidity

A 1 mL sample of gastric juice was mixed with 10 mL of distilled water. Two drops of Topfer's reagent were added, and the solution was titrated against 0.01 N sodium hydroxide (NaOH) until the endpoint was attained. The volume of NaOH consumed at this stage was recorded as the free acidity. Subsequently, 2–3 drops of phenolphthalein indicator were introduced, and the titration was continued until a faint pink coloration persisted. The total volume of NaOH used during the entire titration represented the total acidity. (21)

The acidity was calculated using the following equation:

$$\text{Acidity} = \text{Volume of NaOH} * \text{Normality of NaOH} * 100/0.1 \text{ mEq/L}/100 \text{ gm.}$$

2.6 2.6 Histopathological Evaluation

Following the experimental procedure, gastric tissues were carefully excised and preserved in 10% neutral buffered formalin for fixation. The fixed specimens were subsequently dehydrated through a graded series of ethanol solutions, followed by clearing with xylene and embedding in paraffin wax. Thin tissue sections were prepared



using a microtome and stained with hematoxylin and eosin (H&E). The stained slides were then examined under a light microscope to assess histopathological alterations and the extent of gastric mucosal damage.

2.7 Statistical Analysis

Results were expressed as mean \pm SEM. Statistical comparisons were performed using one-way ANOVA followed by Dunnett's post hoc test. Differences were considered statistically significant at $p < 0.05$.

RESULTS

The present study were performed to assess the gastroprotective potential of whole plant ethanolic extract of agropyran repen in rat against indomethacin induced gastric ulcer. Induction of gastric ulcer produced significant alterations in gastric secretory parameters, evidenced by increased gastric volume, free acidity, total acidity, and reduced gastric pH. The ulcerative effect of indomethacin were effectively maintained, in animal treated with ethanolic extracts of agropyran repen (250mg/kg and 500mg/kg) was taken. Among the five groups ethanolic extract effectively or dose dependently reduced ulcer severity and improved gastric secretory parameters.”

Table : Effect of Indomethacin and agropyran repen extract on the following parameters.

Group	Ulcer index	pH	Gastric volume	Free acidity	Total acidity
Normal	00	3.5 \pm 0.13	1.9 \pm 0.13	19.16 \pm 1.3	39.16 \pm 1.3
Induced	17.73 \pm 3.04	1.5 \pm 0.13	4.8 \pm 0.12	54.16 \pm 1.3	90. \pm 1.2
Low dose	12.12 \pm 4.37	2.5 \pm 0.12	3.3 \pm 0.12	33 \pm 1.12	61 \pm 1.2
High dose	3.19 \pm 2.25	3.15 \pm 0.09	2.5 \pm 0.12	25 \pm 1.2	49 \pm 1.2
Standard	2.66 \pm 1.93	5 \pm 0.12	1.26 \pm 0.10	20.5 \pm 1.7	29 \pm 1.2

All data are expressed as mean \pm SEM (n=6) and analysed with one-way ANOVA followed by Dunnett’ test (****p < 0.0001) and (**p < 0.5)

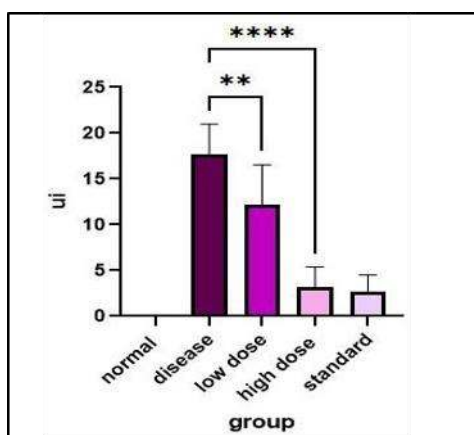


Fig 1. Ulcer index

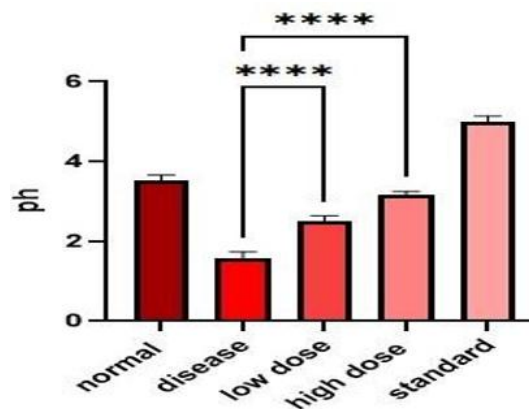


Fig.2 Ph graph

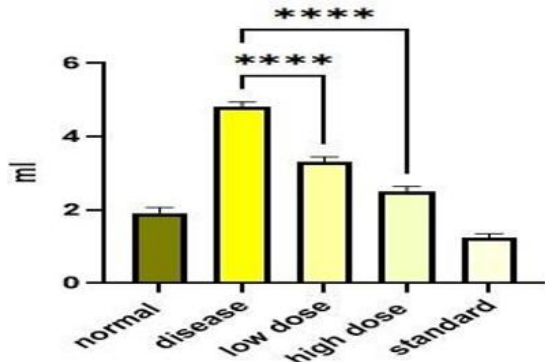


Fig 3. Gastric volume

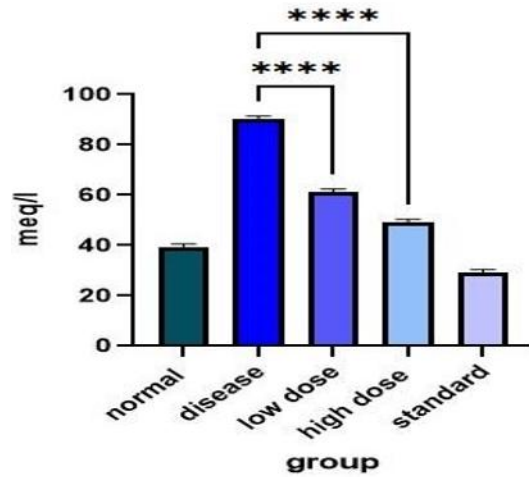


Fig 5. Total acidity

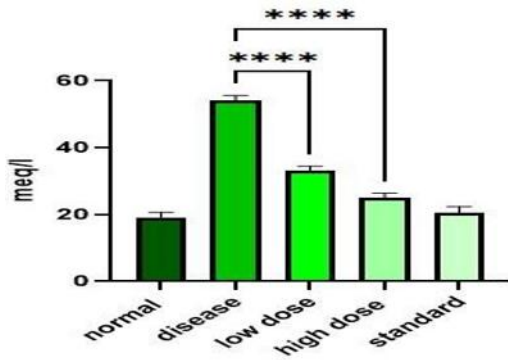


Fig 4. Free acidity

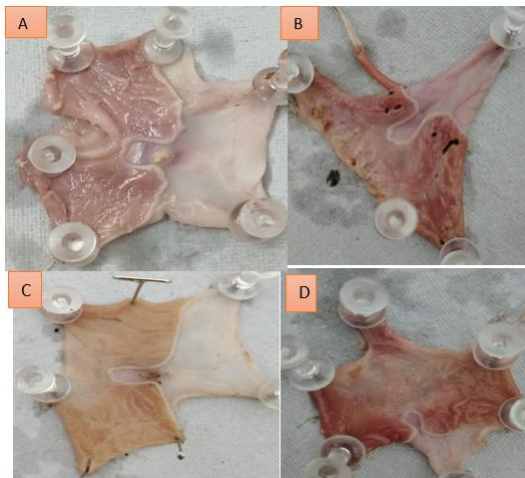
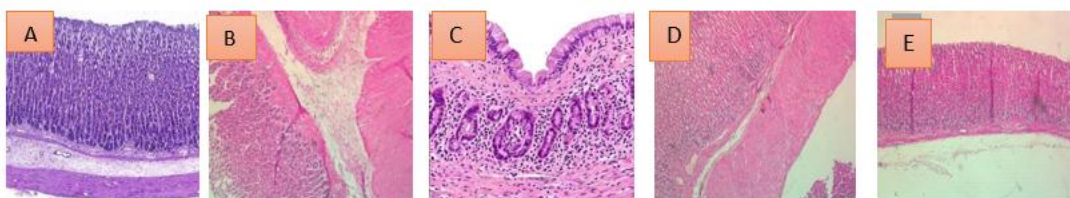


Fig 6. Indomethacin induce gastric ulcer imagination (a)normal (b) indomethacin induced

(c) pretreated low dose of a.repen (d) pretreated high dose of a.repen.

Histopathological studies



- A) Group I- Treated with normal saline : Normal stomach tissue shows healthy intact mucosal cell lining of flattened Epithelial cells. Mucosal glands are seen compactly arranged, consisting of Cells with vesicular nuclei with nucleoli and abundant eosinophilic Cytoplasm
- B) Group II - Treated with Indomethacin : The stomach section of induced rat show hemorrhage and discontinuity in the lining epithelium hyperplastic mucosal glands. shows degenerative changes in the cells, intracellular and Interstitial cell oedema along with degenerative changes in glandular Epithelial cells, areas of hemorrhage and inflammatory cell infiltration with Presence of pigment laden macrophages
- C) Group III- Treated with Omeprazole + Indomethacin : But omeprazole 20 mg/kg has great effect with reduced ulcer formation, mild hyperplastic mucosa with few edema formation. degenerative changes in the cells, denudation of Lining epithelium areas of hemorrhage and inflammatory cells infiltration With presence of pigment laden macrophages. Intracellular and interstitial Cell oedema along with cell degeneration changes in glandular epithelial Cells.
- D) Group IV- Treated with ethanolic extract of Agropyran repen (250 mg/kg) + Indomethacin : The treated animal ethanolic Agropyran repen whole plant extract (250 mg/kg) shows regeneration and reduce inflammatory and ulcerous cell. Shows intact mucosal lining of flattened epithelial cells. Glands are separated by thin strands of fibro connective tissue. Basement membrane is thick and intact. Few bundles of fibrous tissue and occasional blood vessels are seen. Mucosal glands are seen compactly arranged, consisting of cells with Vesicular nuclei with nucleoli
- E) Group V : Treated with ethanolic extract of Agropyran repen (500 mg/kg) + Indomethacin The treated animal Ethanolic Agropyran repen whole plant extract (500 mg/kg, p.o) show no ulcer formation, small atrophic glands, thick muscularis, and edematous sub-mucosa with inflammatory infiltrate . Shows glands are separated by thin strands of fibro connective tissue. Intact Mucosal lining of flattened epithelial cells. Basement membrane is thick and Intact. Few bundles of fibrous tissue and occasional blood vessels are seen. Mucosal glands are seen compactly arranged, consisting of cells with Vesicular nuclei with nucleoli.

DISCUSSION

The present study was undertaken to evaluate the gastroprotective potential of the ethanolic extract of Agropyron repens in an indomethacin-induced gastric ulcer model. Indomethacin is a widely used non-steroidal anti-inflammatory drug (NSAID) known to cause gastric mucosal injury by inhibiting prostaglandin synthesis, leading to increased gastric acid secretion and reduced mucosal defense. Consequently, it serves as a reliable experimental model for assessing anti-ulcer activity. Peptic ulcer disease is a multifactorial disorder that develops when aggressive factors such as gastric acid, pepsin, oxidative stress, and microbial infection outweigh the protective mechanisms of the gastric mucosa. Although currently available anti-ulcer medications are effective, their long-term use may be associated with adverse effects and recurrence of symptoms. Therefore, there is growing interest in identifying safer and more effective therapeutic agents from natural sources. Agropyron repens is a medicinal plant traditionally used for various therapeutic purposes and has been reported to



possess anti-inflammatory, antimicrobial, hypoglycemic, hypolipidemic, diuretic, and antioxidant properties. However, scientific evidence regarding its anti-ulcer potential remains limited. The findings of the present investigation provide preliminary evidence supporting its gastroprotective activity. Administration of the ethanolic extract produced a significant reduction in ulcer index in comparison with the ulcer control group. The extract also decreased gastric volume, free acidity, and total acidity while increasing gastric pH, indicating suppression of gastric secretory activity and enhancement of mucosal protection. These changes suggest that the extract may exert its anti-ulcer effect through both antisecretory and cytoprotective mechanisms. A dose-dependent response was observed, with the higher dose (500 mg/kg) demonstrating greater protection than the lower dose (250 mg/kg). The percentage inhibition of ulcer formation was 31.6% and 82% for the 250 mg/kg and 500 mg/kg doses, respectively. The gastroprotective effect of the higher dose was comparable to that of the standard drug omeprazole (20 mg/kg), which produced 85% inhibition of ulceration. This observation indicates the considerable therapeutic potential of the plant extract. The anti-ulcer activity may be attributed to the presence of bioactive phytoconstituents such as flavonoids, tannins, phenolic compounds, and saponins. These compounds are known to possess antioxidant and anti-inflammatory properties, which may contribute to the maintenance of gastric mucosal integrity, reduction of oxidative damage, and stimulation of protective factors such as mucus and prostaglandins. Overall, the results of the study suggest that the ethanolic extract of *Agropyron repens* possesses significant gastroprotective activity against indomethacin-induced gastric ulcers. The observed effects support its traditional medicinal use and highlight its potential as a natural source for the

development of anti-ulcer agents. Further investigations are required to identify the active constituents and clarify the precise mechanisms responsible for its protective action.

CONCLUSION

The findings of the present study demonstrate that the ethanolic extract of *Agropyron repens* possesses significant gastroprotective activity against indomethacin-induced gastric ulcers in experimental animals. Treatment with the extract resulted in a marked reduction in ulcer index, gastric secretion volume, free acidity, and total acidity, along with an increase in gastric pH when compared with the ulcer control group. Histopathological and macroscopic observations further revealed that pretreatment with the extract effectively minimized gastric mucosal damage, hemorrhagic lesions, and ulcer formation, indicating its protective effect on the gastric lining. The anti-ulcer activity observed may be attributed to the presence of phytoconstituents such as flavonoids, phenolic compounds, tannins, and saponins, which are known to exhibit antioxidant, anti-inflammatory, and cytoprotective properties. The results suggest that *Agropyron repens* has promising potential as a natural anti-ulcer agent. However, additional studies are necessary to elucidate the precise mechanisms involved in its gastroprotective action, isolate and characterize the active constituents, and establish its safety and efficacy through further pharmacological and clinical investigations.

REFERENCES

1. Susser M, Stein Z. Civilisation and peptic ulcer. *Lancet* 1962; 279: 116–19.
2. Sonnenberg A. Causes underlying the birth-cohort phenomenon of Peptic ulcer: analysis of mortality data 1911–2000, England and Wales. *Int J Epidemiol* 2006; 35: 1090–97.



3. Warren JR, Marshall B. Unidentified curved bacilli on gastric Epithelium in active chronic gastritis. *Lancet* 1983; 321: 1273–75.
4. Marshall BJ, Warren JR. Unidentified curved bacilli in the stomach of Patients with gastritis and peptic ulceration. *Lancet* 1984; 323: 1311–15.
5. NIH Consensus Conference. Helicobacter pylori in peptic ulcer Disease. NIH Consensus Development Panel on Helicobacter pylori in peptic ulcer disease. *JAMA* 1994; 272: 65–69.
6. Malfertheiner P, Megraud F, O’Morain C, et al. Current concepts in The management of Helicobacter pylori infection: the Maastricht III Consensus Report. *Gut* 2007; 56: 772–81.
7. Gabriel SE, Jaakkimainen L, Bombardier C. Risk for serious Gastrointestinal complications related to use of nonsteroidal Anti-inflammatory drugs. A meta-analysis. *Ann Intern Med* 1991; 115: 787–96.
8. Garcia Rodriguez LA, Barreales TL. Risk of upper gastrointestinal Complications among users of traditional NSAIDs and COXIBs in The general population. *Gastroenterology* 2007; 132: 498–506.
9. Tsimogiannis D, Oreopoulou V. Classification of Phenolic compounds in plants. In *Polyphenols in Plants* 2019 Jan 1 (pp. 263–284). Academic Press.
10. Aravind SM, Wichienchot S, Tsao R, Ramakrishnan S, Chakkaravarthi S. Role of dietary Polyphenols on gut microbiota, their metabolites And health benefits. *Food Research International*. 2021 Apr 1; 142:110189.
11. Reis A, Rocha S, de Freitas V. Going “Green” in the Prevention and management of atherothrombotic Diseases: The role of dietary polyphenols. *Journal of Clinical medicine*. 2021 Jan;10(7):1490.
12. Annunziata G, Sureda A, Orhan IE, Battino M, Arnone A, Jimenez-Garcia M, Capo X, Cabot J, Sanadgol N, Giampieri F, Tenore GC. The Neuroprotective effects of polyphenols, their role in Innate immunity and the interplay with the Microbiota. *Neuroscience & Biobehavioral Reviews*. 2021 Sep 1; 128:437-53
13. Horrocks JC, De Dombal FT. Clinical presentation of patients with “dyspepsia”. Detailed symptomatic study of 360 patients. *Gut*. 1978;19(1):19-26.
14. ASGE Standards of Practice Committee, Banerjee S, Cash BD, Dominitz JA, Baron TH, Anderson MA, et al. The role of endoscopy in the Management of patients with peptic ulcer disease. *Gastrointest Endosc*. 2010;71(4):663-8. Doi: 10.1016/j.gie.2009.11.026.
15. Chey WD, Leontiadis GI, Howden CW, Moss SF. ACG clinical guideline: treatment of Helicobacter Pylori infection. *Official journal of the American College of Gastroenterology | ACG*. 2017 Feb 1;112(2):212-39
16. Kumar Singh A, Cabral C, Kumar R, Ganguly R, Kumar Rana H, Gupta A, Rosaria Lauro M, Carbone C, Reis F, Pandey AK. Beneficial effects of Dietary polyphenols on gut microbiota and Strategies to improve delivery efficiency. *Nutrients*. 2019 Sep;11(9):2216.
17. Bhandary SK, N. SK, Bhat VS, P. SK, Bekal MP. PRELIMINARY PHYTOCHEMICAL SCREENING OF VARIOUS EXTRACTS OF PUNICA GRANATUM PEEL, WHOLE FRUIT AND SEEDS. *J Heal Allied Sci NU* [Internet]. Dec 2012; 2(4): 34–8.
18. Tiwari U, Rastogi B, Singh P, DSJ of undefined. Immunomodulatory effects of aqueous extract of *Tridax Procumbens* in experimental animals. Elsevier [Internet]. 2004.
19. Perianayagam J, Sharma S, ethnopharmacology KPJ of undefined. Anti-inflammatory activity of *Trichodesma Indicum* root extract in experimental animals. Elsevier [Internet]. 2006.



20. Parmar NS, Hennings G. The gastric antisecretory activity of 3-methoxy-5,7,3',4' tetrahydroxyflavan (ME) – a specific histidine decarboxylase inhibitor in rats. *Agents Actions*. 1984; 15: 143-145.
21. Kulkarni SK. *Handbook of Experimental Pharmacology*. Vallabh Prakashan New Delhi. 2005; 3: 19-84.

HOW TO CITE: Urwela Sahare*, J. V. Vyas, Gastroprotective potential of Agropyren repen in Indomethacin inducing ulcer in experimental animal, *Int. J. of Pharm. Sci.*, 2026, Vol 4, Issue 6, 4849-4858. <https://doi.org/10.5281/zenodo.20757186>

